LEQEMBI(2)-12pp-version 1.pdf 1 28/5/25 12:49 PM

LEQEMBI®

(lecanemab) INJECTION FOR INTRAVENOUS USE | 100 mg/mL

A Guide for Healthcare Professionals

Important Safety Information to Minimise the Risks of Amyloid Related Imaging Abnormalities and Intracerebral Haemorrhage

This document has been approved by HSA as of 08/12/2025 Version 2.0

Contents

Introduction **3**

What is Lecanemab? **4**

Indication 4

Contraindications 4

What is ARIA? **4**

ApoE ε4 carrier status and risk of ARIA 5

Symptoms of ARIA 5

ARIA-E 6

ARIA-H 6

Intracerebral haemorrhage > 1 cm in diameter 6

Monitoring and Managing ARIA **7**

Prior to treatment 7

During treatment 7

ARIA radiographic severity grading 8

Management and dosing recommendations for patients with ARIA 9

ARIA-E 10

ARIA-H 10

Reporting of suspected adverse events **10**

LEQEMBI® (lecanemab) INJECTION FOR INTRAVENOUS USE | 100 mg/mL

Introduction

This guide is intended to provide information for prescribers, radiologists and other treating healthcare professionals about the risk and the management of amyloid related imaging abnormalities (ARIA) and intracerebral haemorrhage (ICH) for patients with early Alzheimer's disease (mild cognitive impairment or mild dementia) receiving lecanemab.

For information particularly relevant for radiologists, please refer to the section titled 'Monitoring and Managing ARIA'.

All patients receiving treatment with lecanemab must be given a Leqembi® Wallet Card by their prescribing physician and counselled about the risk of developing ARIA/ICH and the symptoms to be aware of. Patients must be informed to urgently report any new neurological symptoms to their prescribing physician, or if this is not possible, to any other physician, including their General Practitioner or an emergency doctor. Prescribing doctors should advise their patients to keep the Leqembi® Wallet Card with them at all times and show it to any healthcare professional who may treat them.

To obtain copies of the Leqembi® Wallet Card, please contact the Eisai representative via Eisai (Singapore)'s office mainline: 6296 6977.

This guide contains information to be used in conjunction with the Package Insert for lecanemab, which can be accessed at:
Register of Therapeutic Products

Electronic copies of this guide and the Leqembi® Wallet Card can be found on:
https://www.hsa.gov.sg/educational-materials-for-HCP

What is Lecanemab?

Lecanemab is a humanised immunoglobulin gamma 1 (IgG1) monoclonal antibody which demonstrates high selectivity to amyloid beta (Aβ) aggregate species, with preferential activity for toxic soluble Aβ protofibrils. Lecanemab binds these aggregate Aβ species to neutralise and clear them from the brain. Lecanemab has been shown to produce a reduction in brain amyloid and slow disease progression.

Indication

Lecanemab is indicated for slowing the progression of Alzheimer's disease in patients with mild cognitive impairment or mild dementia stage of disease.

The presence of Aβ pathology must be confirmed using approved methods such as amyloid Positron Emission Tomography (PET) scan or cerebrospinal fluid (CSF) analysis or equivalent validated methods, prior to initiating treatment.

Testing for apolipoprotein E ε4 (ApoE ε4) status must be performed prior to initiation of treatment using a validated test. Prior to testing, the prescribers should discuss with patients the risk of amyloid related imaging abnormalities (ARIA) and provide appropriate counselling. Consider the benefit of lecanemab for the treatment of Alzheimer's disease and potential risk of serious adverse events associated with ARIA when deciding to initiate treatment with lecanemab. The benefit-risk of treatment should be reassessed at regular intervals on an individual basis.

Contraindications

Lecanemab is contraindicated in patients with serious hypersensitivity to lecanemab or to any of the excipients of lecanemab. Reactions include angioedema and anaphylaxis.

What is ARIA?

Amyloid related imaging abnormalities (ARIA) is a consequence of the presence of amyloid in blood vessel walls known as cerebral amyloid angiopathy (CAA). The majority of patients who have Alzheimer's disease also show CAA during neuropathological examination, which can lead to spontaneous ARIA and is associated with an increased risk of intracerebral haemorrhage. Use of monoclonal antibodies directed against aggregated forms of amyloid beta, such as lecanemab, increases the risk of ARIA. Studies have suggested that ARIA may be caused by the disruption of blood vessels with CAA and that the risk is increased by the clearance of amyloid beta from these vessels, but other mechanisms have also been hypothesised.

ARIA can manifest in two distinct forms identifiable through magnetic resonance imaging (MRI):

- ARIA with brain oedema or sulcal effusions (ARIA-E)
- ARIA with haemosiderin deposition (ARIA-H), including microhaemorrhage and superficial siderosis. In addition, intracerebral haemorrhage >1 cm in diameter have occurred.

ARIA-H associated with monoclonal antibodies directed against aggregated forms of amyloid beta generally occurs in association with an occurrence of ARIA-E. ARIA-H of any cause and ARIA-E can occur together.

ApoE ε4 carrier status and risk of ARIA

The ApoE ε4 carrier status is related to the frequency and severity of ARIA and its risk of recurrence.

ApoE ε4 carrier status	ARIA-E	Symptomatic ARIA-E	Recurrence of ARIA-E	ARIA-H	Symptomatic ARIA-H	Recurrence of ARIA-H
Non-carrier	5% (15/278)	1% (4/278)	9% (1/11)	12% (32/278)	1% (2/278)	22% (5/23)
Heterozygotes	11% (52/479)	2% (8/479)	15% (7/48)	14% (66/479)	1% (4/479)	42% (23/55)
Homozygotes	33% (46/141)	9% (13/141)	54% (20/37)	38% (54/141)	4% (5/141)	62% (29/47)

The risk of ARIA, including symptomatic and serious ARIA, is increased in ApoE ε4 homozygotes. The incidence of ARIA was higher in ApoE ε4 homozygotes (45% on lecanemab vs. 22% on placebo) than in heterozygotes (19% on lecanemab vs 9% on placebo) and noncarriers (13% on lecanemab vs 4% on placebo). Among patients treated with lecanemab, symptomatic ARIA-E occurred in 9% of ApoE ε4 homozygotes compared with 2% of heterozygotes and 1% noncarriers. Serious events of ARIA occurred in 3% of ApoE ε4 homozygotes, and approximately 1% of heterozygotes and noncarriers.

The recommendations on management of ARIA do not differ between ApoE ε4 carriers and noncarriers (see section “Management and dosing recommendations for patients with ARIA”).

Testing for ApoE ε4 status must be performed prior to initiation of treatment to inform the risk of developing ARIA. Prior to testing, prescribers should discuss with patients the risk of ARIA across genotypes and the implications of genetic testing results.

Symptoms of ARIA

ARIA usually occurs early in treatment and is usually asymptomatic, although serious and life-threatening events, including seizure and status epilepticus, rarely can occur.

When present, reported symptoms associated with ARIA may include:

- Headache
- Visual changes
- Confusion
- Dizziness
- Focal neurological deficits
- Nausea
- Gait difficulty
- Seizure

Symptomatic ARIA occurred in 3% (29/898) of patients treated with lecanemab in the Phase 3 study (CLARITY AD). Serious symptoms associated with ARIA were reported in 0.7% (6/898) of patients treated with lecanemab.

Symptoms associated with ARIA usually resolve over time. In CLARITY-AD, clinical symptoms associated with ARIA resolved in 79% (23/29) of patients during the period of observation. Similar findings were observed in the Phase 2b study with lecanemab.

ARIA-E

ARIA-E was observed in 13% (113/898) of patients treated with lecanemab compared with 2% (15/897) of patients on placebo. The majority of ARIA-E was asymptomatic, with symptomatic ARIA-E reported in 2.8% (25/898) of patients on lecanemab and no patients on placebo.

The majority of ARIA-E radiographic events occurred early in treatment (within the first 7 doses). The maximum radiographic severity of ARIA-E in patients treated with lecanemab was mild in 4% (37/898) of patients, moderate in 7% (66/898) of patients, and severe in 1% (9/898) of patients. Resolution on MRI occurred in 52% of ARIA-E patients by 12 weeks, 81% by 17 weeks, and 100% overall after detection. Among patients treated with lecanemab, the rate of severe radiographic ARIA-E was highest in ApoE ε4 homozygotes 5% (7/141), compared to heterozygotes 0.4% (2/479) or noncarriers 0% (0/278).

ARIA-H

ARIA-H was observed in 17% (152/898) of patients treated with lecanemab compared with 9% (80/897) of patients on placebo. There was no increase in isolated ARIA-H (i.e., ARIA-H in patients who did not also experience ARIA-E) for lecanemab compared to placebo.

The maximum radiographic severity of ARIA-H microhaemorrhage in patients treated with lecanemab was mild in 9% (79/898), moderate in 2% (19/898), and severe in 3% (28/898) of patients; superficial siderosis was mild in 4% (38/898), moderate in 1% (8/898), and severe in 0.4% (4/898). Among patients treated with lecanemab, the rate of severe radiographic ARIA-H was highest in ApoE ε4 homozygotes 13.5% (19/141), compared to heterozygotes 2.1% (10/479) or noncarriers 1.1% (3/278).

Intracerebral haemorrhage > 1 cm in diameter

Intracerebral haemorrhage > 1 cm in diameter was reported in 0.7% (6/898) of patients in CLARITY AD after treatment with lecanemab compared to 0.1% (1/897) on placebo. Fatal events of intracerebral haemorrhage in patients taking lecanemab have been observed.

Intracerebral haemorrhage >1 cm in diameter occurs randomly throughout the course of treatment in both placebo and lecanemab treated patients.

- Concomitant antithrombotic medication

Baseline use of antithrombotic medication (aspirin, other antiplatelets, or anticoagulants) was allowed in CLARITY AD if the patient was on a stable dose. The majority of exposures to antithrombotic medications were to aspirin. Antithrombotic medications did not increase the risk of ARIA with lecanemab. The incidence of intracerebral haemorrhage was 0.9% (3/328 patients) in patients taking lecanemab with a concomitant antithrombotic medication at the time of the event compared to 0.6% (3/545 patients) in those who did not receive an antithrombotic. Patients taking lecanemab with an anticoagulant alone or combined with an antiplatelet medication or aspirin had an incidence of intracerebral haemorrhage of 2.5% (2/79 patients) compared to none in patients who received placebo.

Intracerebral haemorrhages greater than 1 cm in diameter have been observed in patients taking lecanemab. Additional caution should be exercised when considering the administration of anticoagulants or a thrombolytic agent (e.g. tissue plasminogen activator) to a patient already being treated with lecanemab.

- Other risk factors for intracerebral haemorrhage

Patients were excluded from enrolment in CLARITY AD for findings on neuroimaging that indicated an increased risk for intracerebral haemorrhage. These included findings suggestive of cerebral amyloid angiopathy (prior cerebral haemorrhage > 1 cm in greatest diameter, more than 4 microhaemorrhages, superficial siderosis, vasogenic oedema) or other lesions (aneurysm, vascular malformation) that could potentially increase the risk of intracerebral haemorrhage.

The presence of an ApoE ε4 allele is also associated with cerebral amyloid angiopathy, which has an increased risk for intracerebral haemorrhage.

Caution should be exercised when considering the use of lecanemab in patients with factors that indicate an increased risk for intracerebral haemorrhage and in particular for patients who need to be on anticoagulant therapy.

Monitoring and Managing ARIA

Prior to treatment

- A recent baseline brain MRI should be obtained prior to treatment initiation with lecanemab.
- Testing for ApoE ε4 status must be performed prior to initiation of treatment with lecanemab to inform the risk of developing ARIA.
  - Prior to testing, prescribers should discuss with patients the risk of ARIA across genotypes and the implications of genetic testing results.
  - The management recommendations for ARIA are the same whether an individual is an ApoE ε4 non-carrier, heterozygote or homozygote.
  - The patient should be counselled and acknowledge they understand the risk of ARIA prior to treatment initiation with lecanemab.

During treatment

- Enhanced clinical vigilance for ARIA is recommended during the first 14 weeks of treatment
- If a patient experiences symptoms suggestive of ARIA, clinical evaluation should be performed, including an MRI if indicated

- Regardless, MRI should be performed routinely during treatment, prior to the 5th, 7th and 14th infusions. These scans should be performed using the same protocol as for the baseline MRI scans
- Patients should be reminded about the risk of ARIA at regular intervals during treatment
- The benefit-risk of treatment should be reassessed at regular intervals on an individual basis. Consideration should be given to discontinuing treatment if lecanemab would no longer be expected to be effective.
- In situations where MRI is not feasible, prescribers will need to provide additional risk counselling to patients for an informed decision to be made with regard to the continuation of treatment.

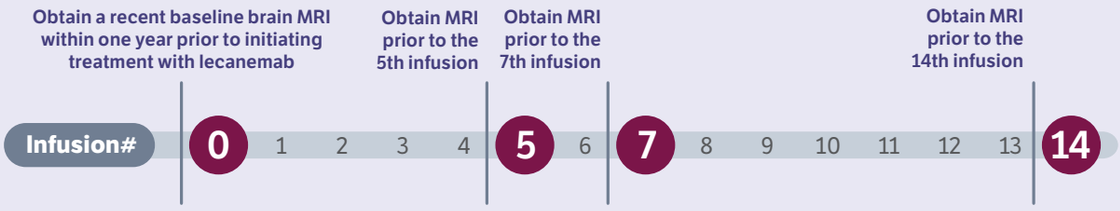

Do NOT administer the 5th, 7th and 14th infusion until the MRIs have been reviewed

ARIA radiographic severity grading

The management of patients with ARIA-E and ARIA-H depends on the presence of clinical symptoms and radiographic severity.

The radiographic severity of ARIA-E, ARIA-H microhaemorrhage and ARIA-H superficial siderosis associated with lecanemab was classified by the criteria shown in the following table.

Table 1: ARIA MRI Classification Criteria

ARIA Type	Radiographic Severity		
	Mild	Moderate	Severe
ARIA-E	FLAIR hyperintensity confined to sulcus and/or cortex/sub-cortex white matter in one location <5cm	FLAIR hyperintensity 5 to 10 cm in single greatest dimension, or more than 1 site of involvement, each measuring <10 cm	FLAIR hyperintensity >10 cm with associated gyral swelling and sulcal effacement. One or more separate/ independent sites of involvement may be noted.
ARIA-H microhaemorrhage	≤ 4 new incident microhaemorrhages	5 to 9 new incident microhaemorrhages	10 or more new incident microhaemorrhages
ARIA-H superficial siderosis	1 focal area of superficial siderosis	2 focal areas of superficial siderosis	> 2 areas of superficial siderosis

Differential diagnosis

ARIA-E should be considered as the presumptive diagnosis when signal abnormalities on MRI are identified in patients recently exposed to monoclonal antibodies that remove amyloid plaque and in whom no evidence of any other inciting cause or underlying lesion can be found.

- In a suspected ARIA case, the full clinical picture must be considered before a diagnosis is confirmed
- MRI is key for the diagnosis and differential diagnosis of ARIA. Scanning at 3.0T is preferred and the use of 1.5T is endorsed as a minimum standard due to the limited availability of high field strength scanners
- The acquisition sequences to identify ARIA include T2* GRE or SWI to detect ARIA-H and T2-FLAIR to detect ARIA-E
- Computed tomography (CT) would not be expected to detect milder forms of ARIA-E and is insensitive to the detection of ARIA-H
- Reliable diagnosis of ARIA may require specific training
- ARIA (detected by MRI) may be mimicked by other pathologies such as ischaemic stroke and posterior reversible encephalopathy syndrome (PRES)
- ARIA can present with focal neurological findings that mimic ischaemic stroke. MRI should be used to evaluate stroke-like symptoms in patients on lecanemab to distinguish ARIA from ischaemic stroke. In addition to acquisition sequences for ARIA, diffusion-weighted imaging (DWI) should be carried out to exclude an ischaemic stroke
    - ARIA-E is not associated with restricted diffusion, thus differentiating it from ischaemia
    - Signs and symptoms of ischaemic stroke, some of which may be seen with ARIA, may include: acute onset, hemiparesis, dysphasia or dysarthria, facial paresis, paraesthesia, eye movement abnormalities, and visual field defects
    - The risk of intracerebral haemorrhage with lecanemab treatment is increased in patients receiving thrombolytic agents

Management and dosing recommendations for patients with ARIA

Dosing recommendations for individuals with ARIA-E and ARIA-H are based on MRI severity and presence of clinical symptoms.

ARIA-E

Table 2: Dosing Recommendations for Patients with ARIA-E

Clinical Symptom Severity[1]	ARIA-E Severity on MRI[2]		
	Mild	Moderate	Severe
Asymptomatic	Consider suspending dosing	Suspend dosing[3]	Suspend dosing[3]
Mild	Suspend dosing[3]		
Moderate or Severe	Suspend dosing[3]		

[1] Clinical Symptom Severity Categories:
Mild: discomfort noticed, but no disruption of normal daily activity. Moderate: discomfort sufficient to reduce or affect normal daily activity.
Severe: incapacitating, with inability to work or to perform normal daily activity.

[2] See Table 1 for MRI severity

[3] Suspend until MRI demonstrates radiographic resolution and symptoms, if present, resolve; consider a follow- up MRI to assess for resolution 2 to 4 months after initial identification. Resumption of dosing should be guided by clinical judgment. Evaluation of risk factors again prior to restarting is recommended. Supportive treatment, including corticosteroids may be considered in case of ARIA-E.

ARIA-H

Table 3: Dosing Recommendations for Patients with ARIA-H

Clinical Symptom Severity	ARIA-H Severity on MRI[1]		
	Mild	Moderate	Severe
Asymptomatic	Consider suspending dosing	Suspend dosing[2]	Suspend dosing[3]
Symptomatic	Suspend dosing[2]		

[1] See Table 1 for MRI severity

[2] Suspend until MRI demonstrates radiographic stabilization and symptoms, if present, resolve; resumption of dosing should be guided by clinical judgment; consider a follow-up MRI to assess for stabilization 2 to 4 months after initial identification. Evaluation of risk factors again prior to restarting is recommended.

[3] Suspend until MRI demonstrates radiographic stabilization and symptoms, if present, resolve; use clinical judgment in considering whether to continue treatment or permanently discontinue lecanemab.

In patients who develop intracerebral haemorrhage greater than 1 cm in diameter during treatment with lecanemab, discontinue treatment.

Reporting of suspected adverse events

Please report any suspected adverse events associated with lecanemab to Vigilance and Compliance Branch, Health Products Regulation Group, Health Sciences Authority at **https://www.hsa.gov.sg/adverse-events**.

All adverse events should also be reported to Eisai (Singapore) Pte Ltd via office mainline 6296 6977 or email **(esn-safety@hhc.eisai.co.jp)**.

By reporting suspected adverse events, you can help provide more information on the safety of this medicine.

LEQEMBI(2)-12pp-version 1.pdf 11 28/5/25 12:49 PM

Picture for illustration only.
Singapore approved packaging may differ from image shown.
Only 200mg/2ml single-dose vial will be supplied in Singapore.

LEQEMBI(2)-12pp-version 1.pdf 12 28/5/25 12:49 PM

Eisai (Singapore) Pte Ltd
152 Beach Road, #15-07 to 08 Gateway East,
Singapore 189721
Tel: 6296 6977 Fax: 6296 6577

SN-LQ-UN-25K-01